



## Giant Dermatofibrosarcoma Protuberans Of The Frontoparietal Area: A Case Report

Adam Rizky<sup>1</sup>, Hatibie Mendy<sup>2</sup>, Yuansun Kosama<sup>3</sup>,  
Tjandra Djony<sup>4</sup>

<sup>1,2,3,4</sup> Divisi Bedah Universitas Sam Ratulangi, Manado, Indonesia

E-mail: [rizky.natanael24@yahoo.com](mailto:rizky.natanael24@yahoo.com), [Mendy.hatibie@unsrat.ac.id](mailto:Mendy.hatibie@unsrat.ac.id), [Yuansunkhosama@gmail.com](mailto:Yuansunkhosama@gmail.com),  
[Djonyedwardtjandra@dosenIB.unsrat.ac.id](mailto:Djonyedwardtjandra@dosenIB.unsrat.ac.id)

### ABSTRACT

#### Keywords:

frontoparietal area, dermatology, giant neoplasm, dermatofibrosarcoma protuberans.

**Background:** Dermatofibrosarcoma protuberans (DFSP) is a rare, slow-growing, low to intermediate-grade soft tissue sarcoma. It is commonly found on the trunk, representing approximately 1-2% of all soft tissue sarcomas. Still, it may also manifest in the extremities or the head and neck, typically in adult patients. It is a locally aggressive neoplasm that tends to infiltrate adjacent structures but with a low potential for metastatic potential. It often presents complex clinical problems due to its high rates of recurrence.

**Purpose:** The study aims to analyze the clinical and histopathological characteristics of DFSP through case reports, as well as provide guidance for effective treatment strategies.

**Method:** We report a case of a 40-year-old male with a complaint of a recurring giant mass of the frontal area. Before the current complaint, the patient had undergone three separate surgeries for a mass growing in the exact location. The pathologic diagnosis was dermatofibrosarcoma protuberans.

**Result:** The patient had undergone three previous surgeries for the same mass, with a histopathological diagnosis of DFSP. After a complete surgical excision with a wider margin, the patient showed no signs of recurrence four months after surgery.

**Conclusion:** Considering the extent of the current mass, excision was chosen as the primary treatment, with wider surgical margins due to the infiltrative growth nature of the neoplasm. The patient was then followed up four months post-operation, showing no signs of recidivism.

### INTRODUCTION

Dermatofibrosarcoma protuberans (DFSP) is a rare, slow-growing, low- to intermediate-grade soft tissue sarcoma originating from the dermal or subcutaneous layer of the skin (Zou et al., 2021) (Mendenhall et al., 2022). It initially presents as a skin-coloured plaque with slight discoloration. (Paramythiotis et al., 2016) Representing approximately 1-2% of all soft tissue sarcomas, it is commonly found on the trunk but may also manifest in the extremities, head, and neck. It typically occurs in adult patients

but may present in all age groups.(Lyu & Wang, 2018) DFSP is a locally aggressive neoplasm that tends to infiltrate adjacent structures but seldom metastasises distally (Stamatakos et al., 2018) (Wiesmueller et al., 2019). DFSP often present complex clinical problems due to its high recurrence rates, mainly when poorly managed (Lyu & Wang, 2018) (Seth & Varshney, 2022).

Slow growth and similarity in nature to benign tumours can lead to delays in diagnosis. Patients often ignore the seemingly harmless initial symptoms, which contributes to the delay in intervention, which can lead to broader development and more severe complications.

Challenges in treating DFSP also include the invasive nature of these neoplasms, which tend to spread to surrounding tissues. Therefore, inadequate surgical excision can increase the risk of recurrence. In addition, histopathological variations can be confusing in the diagnosis process, requiring particular expertise to identify DFSP accurately.

According to Seth & Varshney, (2022), DFSP is an uncommon, slow-growing cutaneous tumour with a characteristic presentation. Cross-sectional imaging findings of the lesions are almost diagnostic. However, lesions may show a different signal intensity on MR images than classically described.

The purpose of this case report is to elucidate the clinical and histopathological characteristics of dermatofibrosarcoma protuberans (DFSP) through patient case studies, present a practical treatment approach for DFSP, especially regarding surgical excision techniques with a wider margin, raise awareness of the importance of early diagnosis and appropriate management to reduce the risk of recurrence in patients with DFSP as well as contribute to a better understanding of the challenges clinical faced in handling DFSP (Li et al., 2017). This research aims to provide better insights into DFSP through detailed case reports. Analysing the case of a patient who has DFSP is hoped to improve understanding of the behaviour of this disease and provide guidance for more effective treatment strategies in the future.

This case report is expected to provide the following benefits: Provide more in-depth insight into the clinical characteristics and behaviours of dermatofibrosarcoma protuberans (DFSP) for medical personnel, provide information on practical treatment approaches, especially surgical excision techniques, which can be applied in clinical practice, increase awareness of the importance of early diagnosis and appropriate management to reduce the risk of recurrence in DFSP patients, to be a reference for future research on DFSP and optimal treatment strategies, and to improve patients' understanding of this condition and the importance of following a prescribed treatment plan.

## **RESEARCH METHODS**

### **CASE REPORT:**

A 40-year-old male presented with a recurring giant mass of the frontal area. Before the current complaint, the patient underwent three mass-growing surgeries in the exact location. The mass has been increasing progressively from the frontal region, extending vertically, deforming the head (Fig. 1). Considering the extent of the current mass, excision was chosen as the primary treatment, with wider surgical margins due to the infiltrative growth nature of the neoplasm (Fig. 2). The pathologic diagnosis was dermatofibrosarcoma protuberans (Fig. 3). During a follow-up session four months post-operation, the patient showed no signs of recidivism (Fig. 4).

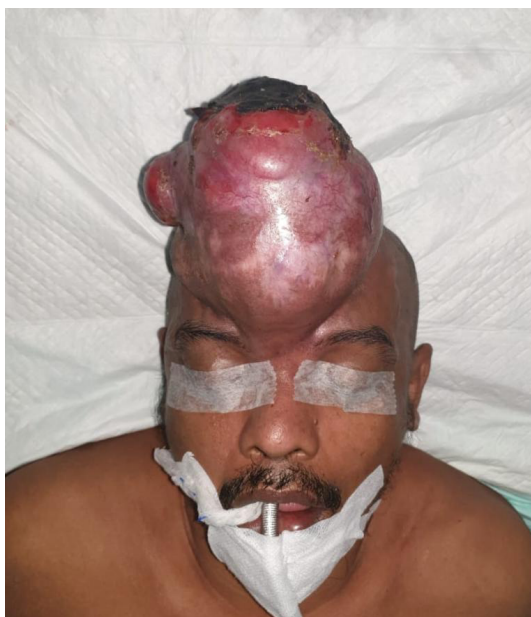

Figure 1. Front display of the giant dermatofibrosarcoma protuberans before the surgery.

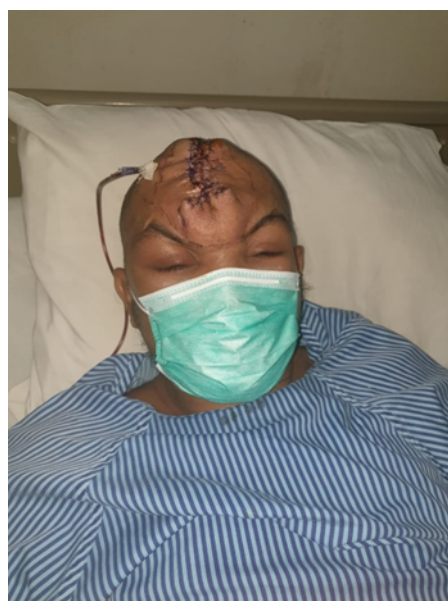

Figure 2. Complete removal of the giant dermatofibrosarcoma protuberans.

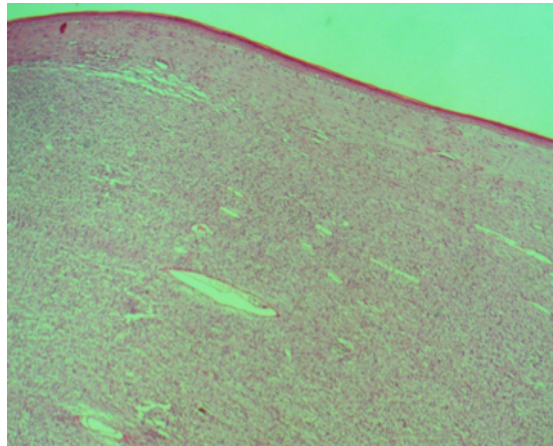
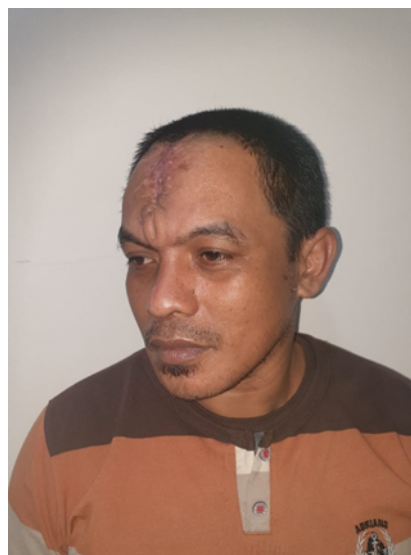

Figure 3. Histologic appearance of the dermal lesion: poorly demarcated, consisting of spindle-like cells with atrophied epidermis.



## RESULTS AND DISCUSSION

DFSP is a rare, slow-growing soft tissue sarcoma often mistaken for a benign tumour (Felek et al., 2019) (Alnooh et al., 2021). It usually appears as a pink-reddish plaque that evolves into multiple invasive ‘protuberant’ nodules. (Paramythiotis et al., 2016) It has several histopathological variants: pigmented, myxoid, myoid, granular cell, sclerotic, atrophic, and giant cell neuroblastoma. (Lyu & Wang, 2018)

It is very challenging to diagnose a DFSP accurately; thus, histological confirmation remains a gold standard. Due to the neoplasm's aggressive and invasive nature, early diagnosis remains critical for optimal clinical outcomes. (Lyu & Wang, 2018) (Jing et al., 2021). Other masses may be considered as differential diagnoses for the DFSP, such as the lipoma, epidermal cyst, keloid, dermatofibroma in early stages, and pyogenic granuloma, Kaposi sarcoma, and other soft tissue sarcomas in latter stages (Paramythiotis et al., 2016; Ramirez-Fort et al., 2020; Sheidaei et al., 2023).

Due to the infiltrative growth nature of the neoplasm, the chosen management strategy for DFSP is complete surgical excision with wider surgical margins, including surrounding affected tissues. However, some literature has proposed Mohs micrographic

surgery as a gold standard of treatment. The efficacy of other alternatives, i.e., radiotherapy, tyrosine kinase inhibitor administration, and chemotherapy, are only considered for selected cases with inadequate margins or recurrence, with better outcomes when combined with surgery (Llombart et al., 2013) (Hao et al., 2020).

This patient received a wide excision with skin preservation. The periosteum was also involved in tumour mass removal. This case has demonstrated that a properly executed wide, complete surgical excision can lead to favourable clinical outcomes without signs of recidivism four months after surgery. This is in line with the present literature.

Dermatofibrosarcoma protuberans is a notoriously recurring, rare soft tissue neoplasm commonly found in adults. Poorly treated, this initially slow-growing neoplasm poses serious invasion potential to surrounding tissues. The exact diagnosis requires a histopathological examination. Surgical excision with wider surgical margins will provide the most favourable clinical outcome.

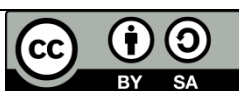### **CONCLUSION**

Dermatofibrosarcoma protuberans (DFSP) is a rare and recurrent soft tissue neoplasm, most commonly found in adult patients. This case shows that although DFSP is initially slow-growing, it can be seriously invasive to surrounding tissues if not treated appropriately. An accurate diagnosis requires histopathological examination, and the primary recommended treatment is complete surgical excision with a broader margin to reduce the risk of recurrence. The results of the treatment of patients in this study showed no signs of recurrence after four months postoperatively, which is in line with the existing literature. Early and appropriate treatment of DFSP is essential to achieve optimal clinical outcomes.

### **REFERENCES**

- Alnooh, A., Al-Qubaisy, Y., Alshammari, N., & Alhowshan, I. (2021). Dermatofibrosarcoma protuberans: a systematic review of the literature. *Journal of Pharmaceutical Research International*, 33(60A), 885–891.
- Felek, S. A., İbas, M., Dursun, S., & Heper, A. O. (2019). Dermatofibrosarcoma protuberans of the neck: A brief review of the literature. *Indian Journal of Otolaryngology and Head & Neck Surgery*, 71(Suppl 1), 369–372.
- Hao, X., Billings, S. D., Wu, F., Stultz, T. W., Procop, G. W., Mirkin, G., & Vidimos, A. T. (2020). Dermatofibrosarcoma protuberans: update on the diagnosis and treatment. *Journal of Clinical Medicine*, 9(6), 1752.
- Jing, C., Zhang, H., Zhang, X., & Yu, S. (2021). Dermatofibrosarcoma protuberans: a clinicopathologic and therapeutic analysis of 254 cases at a single institution. *Dermatologic Surgery*, 47(2), e26–e30.
- Li, Y., Wang, C., Xiang, B., Chen, S., Li, L., & Ji, Y. (2017). Clinical features, pathological findings and treatment of recurrent dermatofibrosarcoma protuberans. *Journal of Cancer*, 8(7), 1319.
- Llombart, B., Serra-Guillén, C., Monteagudo, C., Guerrero, J. A. L., & Sanmartín, O. (2013). Dermatofibrosarcoma protuberans: a comprehensive review and update on diagnosis and management. *Seminars in Diagnostic Pathology*, 30(1), 13–28.
- Lyu, A., & Wang, Q. (2018). Dermatofibrosarcoma protuberans: A clinical analysis.

- Oncology Letters*, 16(2), 1855–1862. <https://doi.org/10.3892/ol.2018.8802>
- Mendenhall, W. M., Scarborough, M. T., Flowers, F. P., Maki, R., Robinson, J. K., Pollock, R. E., & Shah, S. (2022). Dermatofibrosarcoma protuberans: epidemiology, pathogenesis, clinical presentation, diagnosis, and staging. *UpToDate. Post TW (Ed): UpToDate, Waltham, MA.*
- Paramythiotis, D., Stavrou, G., Panagiotou, D., Petrakis, G., & Michalopoulos, A. (2016). Dermatofibrosarcoma protuberans: a case report and review of the literature. *Hippokratia*, 20(1), 80–83.
- Ramirez-Fort, M. K., Meier-Schiesser, B., Niaz, M. J., Niaz, M. O., Feily, A., Fort, M., Lange, C. S., & Caba, D. (2020). Dermatofibrosarcoma protuberans: The current state of multidisciplinary management. *Skinmed*, 18(5), 288–293.
- Seth, N., & Varshney, D. (2022). Dermatofibrosarcoma Protuberans-Case Report and Review of Literature. *Journal of Evolution of Medical and Dental Sciences*, 801–804.
- Sheidaei, S., Salehi, M., Abedian kenari, F., & Jafari, H. R. (2023). Dermatofibrosarcoma protuberans challenges: a case series and review of the literature. *Journal of Medical Case Reports*, 17(1), 18.
- Stamatakis, M., Fyllos, A., Siafogianni, A., Ntzeros, K., Tasiopoulou, G., Rozis, M., & Kontzoglou, K. (2018). *Dermatofibrosarcoma protuberans: a rare entity and review of the literature.*
- Wiesmueller, F., Agaimy, A., Perrakis, A., Arkudas, A., Horch, R. E., Grützmann, R., & Vassos, N. (2019). Dermatofibrosarcoma protuberans: surgical management of a challenging mesenchymal tumor. *World Journal of Surgical Oncology*, 17, 1–9.
- Zou, M.-H., Huang, Q., Yang, T., Jiang, Y., Zhang, L., Xie, Y., & Zheng, R.-Q. (2021). Role of ultrasound in the diagnosis of primary and recurrent dermatofibrosarcoma protuberans. *BMC Cancer*, 21(1), 909.



**This work is licensed under a [Creative Commons Attribution-ShareAlike 4.0 International License](https://creativecommons.org/licenses/by-sa/4.0/).**